

2023-07-28

Top tips for minimally invasive dentistry in primary care

Lin, Y

<https://pearl.plymouth.ac.uk/handle/10026.1/21082>

10.1038/s41415-023-6127-8

British Dental Journal

Springer Science and Business Media LLC

All content in PEARL is protected by copyright law. Author manuscripts are made available in accordance with publisher policies. Please cite only the published version using the details provided on the item record or document. In the absence of an open licence (e.g. Creative Commons), permissions for further reuse of content should be sought from the publisher or author.

Top Tips for Minimally Invasive Dentistry in Primary Care

Yen Lin¹, Ewen McColl², Henry F. Duncan³

¹Clinical Lecturer in Dental Education, Peninsula Dental School (University of Plymouth), Portland Square, Plymouth, PL4 8AA.

²Director of Clinical Dentistry, Peninsula Dental School (University of Plymouth), Derriford Dental Education Facility, Plymouth Science Park, Research Way, Plymouth, PL6 8BT.

³Division of Restorative Dentistry and Periodontology, Dublin Dental University Hospital, Trinity College Dublin, Dublin, Ireland, D02 F859

Introduction

Minimally invasive dentistry (MID) (or minimal intervention dentistry) is defined as a holistic approach which respects the dental tissues and patient's comfort and aims to help maintain long-term oral health centred around preventive, patient-focused care plans with the management of patients' needs and expectations^{1,2}. It recognises that caries is a multifactorial, life-style associated condition which can be modified with behavioural modifications³. Caries can also be managed without removing all microorganisms involved with the focus shifting to arresting the lesion instead⁴. Management can be divided into four stages: Identify, prevent, restore and recall.

In this paper, we discuss the Top Tips for carrying out MID, and further explore the four stages involved in the management of caries.

Identify

This stage allows clinicians to identify the aetiology behind the prevalence of caries for each patient and also assess the extent of damage.¹ A risk assessment-based approach aimed at disease prevention and patient management should be undertaken, considering risk indicators, risk factors and protective factors, which can lead to the demineralisation of teeth and plan for prevention or restoration of them in the subsequent phases^{2,5}. This also aids in tailoring of the individual patient care plan and recall intervals.

Risk indicators include previous caries experience, presence of active cavitated lesions and white spot lesions as well as the number of restorations in the last 6 months. The site of the lesions may also play a role, for example, patients with defective restorations, exposed root surfaces and posterior teeth with deep fissures may increase their caries risk as these are recognised as difficult to clean areas.

Sociodemographic factors should also be considered, and this can include age, educational background and disabilities which can impact their ability to access and maintain dental care. The following patient groups are considered high risk based on their sociodemographic background: Dependent elderly people, disabled people, people with chronic conditions, people from disadvantaged socio-economic backgrounds, migrant and prison populations, pregnant women, people with drug-induced xerostomia, as well as people who have had head and neck radiotherapy or who are involved in the food industry.⁶

Risk factors can be categorised as local, systemic and behavioural. Systemic risk factors include an individual's environment and this can include their living conditions, disorder and medication, age,

genetics and physiological behaviours.⁶ Behavioural risk factors relate specifically to the individual and can be modified which usually encompasses their dietary habits, oral hygiene measures, smoking habits or emotional stress. Lastly, local risks factors are involved in the disease activity and these include salivary flow, plaque retention factors, periodontal biotype and structural dental abnormalities.

Protective factors mainly encompass the frequency of fluoride exposure and this can stem from toothbrushing habits with fluoride toothpaste as well as living in an area which has fluoridated water.

In children, the recommended age for a dental visit is by the first year of age or eruption of the first deciduous tooth.⁷ This will allow the dentist to establish rapport with the patient as well as encourage participation amongst members of the family. The use of distractors and positive reinforcement will aid the clinician to assess the dentition and surrounding soft tissues. Risk assessment of children is important too as it allows all parties involved to identify patients at high risk of early childhood caries and design treatment and preventative protocols to manage this. In addition to the above risk factors, additional risk factors would include assessing whether the child sleeps with a bottle or consumes liquids other than water for an extended period.

In detecting the activity state of a carious lesion, the appearance and position of the lesion should be considered in conjunction with gentle tactile probing and the gingival status of the surrounding tissues.⁸ Pre-cleaning the teeth can improve direct visual examination and this can be carried out with a rotary brush and prophylaxis paste. The teeth are then air dried and the use of magnification with good illumination should be considered which can improve the detection rate of carious lesions. Clinical indicators of lesion activity can include the presence of biofilm on the lesion, gingival condition as well as lesion texture, hardness and appearance (**Figure 1**)⁴.

Bitewing radiographs are the gold standard for detecting proximal lesions and should also be used in the detection of carious lesions.^{8,9} Radiographs will also allow at least a cursory division of the depth of caries into shallow, moderate, deep and extremely deep caries which will aid in treatment planning. Recently, there has been the development of new diagnostic tools e.g. dyes, transillumination, infrared lasers, LED cameras, electrical conductance and fluorescence systems in caries detection but these should be used with care as they may under- or over-detect the presence of caries.

Prevent

This stage aims to restore balance between the pathological and protective factors involved as well as eliminate and minimise disease risk factors by modifying lifestyle behaviour^{1,10}. Preventive measures aimed at remineralisation of the tooth surfaces should be initiated and encouraged. This involves an emphasis on promoting oral hygiene and good dietary habits and the cessation of smoking and destructive drinking habits as well as drug use⁴. Patients should be encouraged to undergo plaque removal at least twice a day with a manual toothbrush, rotating or oscillating toothbrush and a 'pea-sized' amount of 1350-1500ppm fluoride toothpaste. Interproximal cleaning should also be encouraged via the use of interdental brushes, floss or soft toothpicks.⁶ One can consider the use of a water jet in patients who lack the manual dexterity as well as the use of a disclosing dye to highlight areas which are missed during brushing.

In addition, a diet diary as part of a caries-risk assessment can be considered which can monitor patients' 'acid attacks'.⁸ Once oral hygiene measures are optimal, the prescription of topical fluoride supplements can be considered e.g. 5000ppm fluoride toothpaste, 0.05% sodium fluoride

mouthwash as well as the placement of fissure sealants (resin, GIC, RMGIC or compomers) or topical 22,600ppm fluoride varnish at 3-6 month intervals depending on the caries risk. Products containing CPP-ACP (casein phosphopeptide-amorphous calcium phosphate) have also been recently introduced but these should be used with caution as there is lack of evidence regarding their effectiveness¹¹.

In children, the correct use of toothbrushing techniques should be demonstrated to the carer via the 'tell-show-do' technique.⁷ The amount of toothpaste required should also be reduced, with a smear being sufficient for children under the age of two years.

Behaviour management not only applies to children but adults as well and successful motivation will aid in reducing their modifiable risk factors. This can be undertaken via understanding the patients' views on their oral health, identifying their limitations, improving their self-esteem by paying attention to them and setting SMART objectives in the long term.⁶

Restore

In this stage, the decision to intervene should take into consideration lesion activity, cavitation, depth and cleansability of the lesion⁴. Treatment should be focused on minimally invasive operative intervention, resolution of symptoms if present, as well as the repair instead of replacement of defective restorations. The former will preserve tooth structure and pulp sensibility whereas the latter increases the size of the cavity and can weaken the overall structural integrity of the tooth^{1,10,12}. It should also be noted that the success of this stage is affected by previous stages and can lead to failure of restorations if aetiological factors are not identified and managed. Restoration of a carious lesion aims to reduce any further loss of dental tissue, remove any plaque retentive factors which may present in a cavity as well as restore occlusion, function and aesthetics of an individual. The use of durable, bioactive, adhesive, restorative materials e.g. resin-based composite, glass ionomer cement (GIC), hydraulic calcium silicate cements are also advocated as this negates the need to destroy 'sound' tooth structure to achieve mechanical retention¹².

Atraumatic Restorative Treatment (ART)

Atraumatic restorative treatment (ART) can be considered as an initial stabilisation phase prior to a definitive restoration. This can be used as an alternative to selective caries removal in deep caries lesions that are in close proximity to the pulp radiographically, which run the risk of pulpal exposure should non-selective removal of carious dentine be undertaken (**Figure 1**)¹³. This technique can also be used in children if there is insufficient compliance to employ the use of a fast handpiece under local anaesthesia.⁷

This technique is carried out by selective removal of necrotic tissue and leaving a layer of affected carious dentine on the floor of the cavity to reduce the microbial load. Hard stained and discoloured dentine should be left in-situ as this has the potential to remineralise. Any unsupported enamel which is thin and weak should be removed as these are prone to fracture. The use of rotary instrumentation relies on tactile feedback that results in the unnecessary removal of 'sound' tooth tissues as clinicians tend to want to remove all soft affected dentine. Isolation of the surrounding area with cotton wool rolls are usually sufficient to reduce contamination of the area and aid moisture control.

Following this, the smear layer is removed using a dentine conditioner before a GIC restoration is placed which reduces the surface area for retention of the plaque biofilm and allows for ion exchange leading to remineralisation of any demineralised tissues³. GIC also provides a long-lasting

seal via chemical adhesion that deprives any remaining bacteria of nutrients as well as reduces the risk of inducing inflammation in the pulp. Pits and fissures can also be sealed using the 'finger-press technique' which reduces the risk of bacterial ingress leading to decay ¹⁴.

Resin Infiltration

Resin infiltration is more commonly used in the management of white spot non-cariou lesions but can also be used in the management of caries which halts the demineralisation process and stabilises the carious lesion ¹⁵. It is usually indicated in initial proximal lesions and non-proximal smooth surfaces, but should not be used on cavitated lesions as resin infiltration is poor. 15% hydrochloric acid gel should be applied for 2 minutes to etch the tooth, followed by dehydration of the tooth with 99% ethanol and air. A low viscosity TEGDMA-type resin is then applied, which forms a mechanical barrier which removes the source of nutrients for bacteria to feed on. It also impedes further acid diffusion and mineral loss ⁴.

Sono-Abrasion

Sono-abrasion works on the principles of vibration, abrasion, thermal and cavitation, which can be selectively used in the treatment of small lesions and aims to preserve tissue as much as possible and stimulate pulpal repair mechanisms ¹⁶. A variety of abrasive powders can be used which allows for conservative cavity preparations and produces rounded cavity line angles which reduces stress during polymerisation shrinkage ¹². This reduces the risk of chipping, loss of residual enamel and damage to adjacent tooth surfaces and optimises marginal adaptation of restorations. It is also used in the operative management of primary and secondary lesions and the improvement of the quality of occlusal, approximal and cervical margins. This technique also has its uses in aesthetic dentistry, as it can be used for the preparation, recontouring and finishing of margins of ceramic or indirect resin-based composite restorations.

Other Techniques

Other minimally invasive techniques for caries removal include chemo-mechanical caries removal using a hypochlorite/ amino acid based gel system which allows for selective removal of infected and affected dentine ¹⁷. This technique however is technique-sensitive and requires sufficient clinician training to ensure its proper use.

Recall

Lastly, this stage focuses on establishing an appropriate recall period depending on the individual's caries risk to allow for monitoring of the disease and maintenance of the dentition. ¹ This also allows for reinforcement of the patient's education, monitoring the effectiveness of preventative and control measures implemented by the clinician as well as checking the integrity of any restorations provided in the previous stage. ⁷ Any potential failures can be identified and a new caries risk and recall interval assigned to the patient. Any suspicious lesions should be monitored with preventative strategies before invasive intervention if there are any doubts about the disease activity as this will reduce the potential of over-treatment ¹¹.

Conclusions

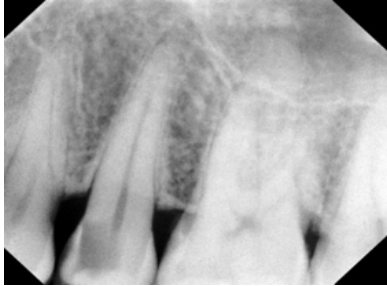
Early identification of carious lesions will reduce the need for operative intervention and delay the start of a 'restorative spiral' for the affected teeth. If treatment is advocated, one should ensure that this respects and conserves healthy tooth tissue and maintains pulp vitality. In this short paper, we

have highlighted the importance of the identification of risk factors and carious lesions which will allow the clinician to tailor a treatment plan to include prophylactic measures and minimal restorative intervention as well as establish a recall period to monitor the progression of the disease.

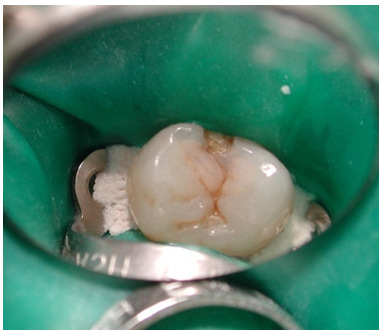
Correspondence-Ewen McColl-ewen.mccoll@plymouth.ac.uk

Figure Legends

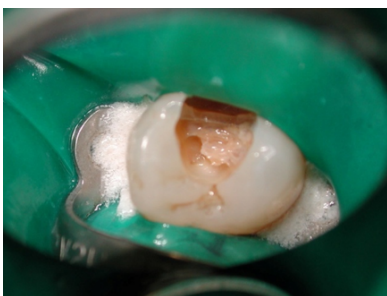
Figure 1



- A) Periapical radiograph of the upper left second premolar showing a mesial radiolucency indicative of deep caries (extending into inner third of dentine radiographically)



- B) Clinical photograph of the same tooth as A with cavitation evident mesially and 'yellow' carious tissue.



- C) Cavity after unsupported caries removal reveals soft 'yellow' carious dentine indicative of an active lesion. Non-selective (complete) removal of the carious tissue around the margins and periphery of the cavity will facilitate 'carious' dentine to be left over the aspect of the cavity in proximity to the pulp avoiding pulp exposure.

References

1. Featherstone JDB, Doméjean S. Minimal intervention dentistry: part 1. From 'compulsive' restorative dentistry to rational therapeutic strategies. *British Dental Journal*. 2012;213(9):441-5.

2. Banerjee A. 'Minimum intervention' – MI inspiring future oral healthcare? *British Dental Journal*. 2017;223(3):133-5.
3. Ngo H, Opsahl-Vital S. Minimal intervention dentistry II: part 7. Minimal intervention in cariology: the role of glass-ionomer cements in the preservation of tooth structures against caries. *British Dental Journal*. 2014;216(10):561-5.
4. Banerjee A, Splieth C, Breschi L, Fontana M, Paris S, Burrow M, et al. When to intervene in the caries process? A Delphi consensus statement. *British Dental Journal*. 2020;229(7):474-82.
5. Doméjean S, Banerjee A, Featherstone JDB. Caries risk/susceptibility assessment: its value in minimum intervention oral healthcare. *British Dental Journal*. 2017;223(3):191-7.
6. Lallam C, Decup F. Minimal intervention dentistry II: part 2. Management of caries and periodontal risks in general dental practice. *British Dental Journal*. 2014;216(4):179-85.
7. Ramos-Gomez FJ, Crystal YO, Domejean S, Featherstone JDB. Minimal intervention dentistry: part 3. Paediatric dental care – prevention and management protocols using caries risk assessment for infants and young children. *British Dental Journal*. 2012;213(10):501-8.
8. Guerrieri A, Gaucher C, Bonte E, Lasfargues JJ. Minimal intervention dentistry: part 4. Detection and diagnosis of initial caries lesions. *British Dental Journal*. 2012;213(11):551-7.
9. Fontana M, Gonzalez-Cabezas C. Minimal intervention dentistry: part 2. Caries risk assessment in adults. *British Dental Journal*. 2012;213(9):447-51.
10. Dawett B, Atkins B, Banerjee A. A guide to building 'MI' oral healthcare practice. *British Dental Journal*. 2017;223(3):223-7.
11. Holmgren C, Gaucher C, Decerle N, Doméjean S. Minimal intervention dentistry II: part 3. Management of non-cavitated (initial) occlusal caries lesions – non-invasive approaches through remineralisation and therapeutic sealants. *British Dental Journal*. 2014;216(5):237-43.
12. Mackenzie L, Banerjee A. Minimally invasive direct restorations: a practical guide. *British Dental Journal*. 2017;223(3):163-71.
13. by: ESoEd, Duncan HF, Galler KM, Tomson PL, Simon S, El-Karim I, et al. European Society of Endodontology position statement: Management of deep caries and the exposed pulp. *International Endodontic Journal*. 2019;52(7):923-34.
14. Holmgren CJ, Roux D, Doméjean S. Minimal intervention dentistry: part 5. Atraumatic restorative treatment (ART) – a minimum intervention and minimally invasive approach for the management of dental caries. *British Dental Journal*. 2013;214(1):11-8.
15. Lasfargues JJ, Bonte E, Guerrieri A, Fezzani L. Minimal intervention dentistry: part 6. Caries inhibition by resin infiltration. *British Dental Journal*. 2013;214(2):53-9.
16. Decup F, Lasfargues JJ. Minimal intervention dentistry II: part 4. Minimal intervention techniques of preparation and adhesive restorations. The contribution of the sono-abrasive techniques. *British Dental Journal*. 2014;216(7):393-400.
17. Banerjee A. Minimal intervention dentistry: part 7. Minimally invasive operative caries management: rationale and techniques. *British Dental Journal*. 2013;214(3):107-11.