

2020

Use of preoperative cone-beam computed tomography to aid in establishment of endodontic working length: A systematic review and meta-analysis

Paterson, A

<https://pearl.plymouth.ac.uk/handle/10026.1/20830>

10.5624/isd.2020.50.3.183

Imaging Science in Dentistry

Korean Academy of Oral and Maxillofacial Radiology

All content in PEARL is protected by copyright law. Author manuscripts are made available in accordance with publisher policies. Please cite only the published version using the details provided on the item record or document. In the absence of an open licence (e.g. Creative Commons), permissions for further reuse of content should be sought from the publisher or author.

Use of preoperative cone-beam computed tomography to aid in establishment of endodontic working length: A systematic review and meta-analysis

Andrew Paterson¹, Vittorio Franco², Shanon Patel¹, Federico Foschi^{1,3,*}

¹Department of Endodontics, The Faculty of Dentistry, Oral and Craniofacial Sciences at Kings' College London, London, United Kingdom

²UK Dental Specialists, UKDS, St. Alban, United Kingdom

³Department of Therapeutic Dentistry, Institute of Dentistry, I. M. Sechenov First Moscow State Medical University, Moscow, Russia

ABSTRACT

Purpose: This study was performed to assess the accuracy of preoperative cone-beam computed tomography (CBCT), when justified for other reasons, in locating the apical foramen and establishing the working length.

Materials and Methods: Six electronic databases were searched for studies on this subject. All studies, of any type, were included if they compared measurements of working length with preoperative CBCT to measurements using an electronic apex locator (EAL) or histological reference standard. Due to the high levels of heterogeneity, an inverse-variance random-effects model was chosen, and weighted mean differences were obtained with 95% confidence intervals and *P* values.

Results: Nine studies were included. Compared to a histological reference standard, CBCT indicated that the apical foramen was on average 0.40 mm coronal of its histological position, with a mean absolute difference of 0.48 mm. Comparisons were also performed to an EAL reference standard, but the conclusions could not be considered robust due to high levels of heterogeneity in the results.

Conclusion: A low level of evidence is produced suggesting that preoperative CBCT shows the apical foramen to be on average 0.40 mm coronal to its histological position, with a mean absolute difference of 0.48 mm. (*Imaging Sci Dent 2020; 50: 183-92*)

KEY WORDS: Tooth Apex; Cone-Beam Computed Tomography; Meta-Analysis; Dental Pulp Cavity

Introduction

Preoperative cone-beam computed tomography (CBCT) should not be used for the sole purpose of estimating the endodontic working length. However, with increasing numbers of tomograms being taken for other reasons, CBCT could still be helpful in the estimation of this measurement.

It is important that the positions of endodontic files, irrigation needles, and obturation are controlled in relation to specific topographical landmarks on the internal surface of the apical root canal wall. Several topographical

landmarks have been described, notably the apical foramen (AF) (also known as the major diameter), the apical constriction (AC) (also known as the minor diameter), and the apical vertex (AV). The classical description is that the root canal is widest at the coronal orifice and tapers apically to its narrowest point, the AC, which is near the root apex. The canal is then described as widening for a short period in a funnel shape until it reaches the AF, which is the point where the canal meets the external surface of the root. Often, the AF is not located at the most apical portion of the root (the AV) but rather is slightly or markedly offset.¹

Establishing the true positions of the AC and AF is important. Many endodontists believe that the working length should be terminated at the AC because this will create the smallest possible wound and promote healing.² These clinicians believe that the extension of instruments,

Received December 15, 2019; Revised April 14, 2020; Accepted April 26, 2020

*Correspondence to : Prof. Federico Foschi

Endodontic Postgraduate Unit, The Faculty of Dentistry, Oral and Craniofacial Sciences at Kings' College London, Floor 22, Tower Wing, Guy's Hospital, St Thomas' St, London SE1 9RT, UK

(Tel) 44-20-7188-1573, E-mail) federico.foschi@kcl.ac.uk

Copyright © 2020 by Korean Academy of Oral and Maxillofacial Radiology

This is an Open Access article distributed under the terms of the Creative Commons Attribution Non-Commercial License (<http://creativecommons.org/licenses/by-nc/3.0>) which permits unrestricted non-commercial use, distribution, and reproduction in any medium, provided the original work is properly cited.

Imaging Science in Dentistry · pISSN 2233-7822 eISSN 2233-7830

irrigant, endodontic core materials, or sealers to or beyond the AF affects healing due to damage to periapical tissues.² Other endodontists argue that this approach could leave a portion of potentially infected canal between the AC and AF untouched by mechanical or chemical debridement. Currently, insufficient high-quality evidence is available to provide definitive answers to these questions.³

Several techniques exist for establishing the location of these landmarks and therefore the working length. Each has advantages and disadvantages, and accuracy varies. Periapical radiographs can only be used to identify the radiographic apex (RA), which correlates with the AV rather than the AC or AF, and often leads to overestimation of the working length.

Electronic apex locators (EALs) are believed to be usable to locate the AC and AF; however, their accuracy is subject to debate. The accuracy of EALs was first assessed in relation to the RA, but this has limited validity, as the RA and AF are often substantially offset.⁴ While subsequent studies involved the longitudinal sectioning of extracted teeth, micro-computed tomography (micro-CT) studies have since revealed the inaccuracies of this technique.^{5,6}

In a recent study, micro-CT was used to measure the accuracy of EALs, since the former is highly valid for locating the true position of the AC.⁷ That study demonstrated that several apex locators were highly accurate in identifying the AC and AF. The only drawback of the *in vitro* study was the use of electroconductive materials to replace the periodontal ligament and extracted teeth.⁷ The validity of this technique is questionable, as it is unclear whether the electroconductive materials can replicate the exact functioning of the periodontal ligament.⁸

CBCT is a relatively new radiographic imaging system that can provide images in 3 dimensions. Recently, it has been established that the AF can be identified on preoperative CBCT, and proprietary measuring software can be used to measure its distance from a coronal reference point (CRP).⁹⁻¹¹

The main concern related to radiographic imaging is that it may cause a patient to develop cancer years after an exposure (a somatic stochastic effect).¹² Any radiographic imaging must show a potential net benefit to the patient over the risks of malignant change from exposure, considering the efficacy, benefits, and risks of available alternative techniques. Unfortunately, even under optimized conditions, CBCT provides a dose that is 4 to 10 times higher, and therefore carries a higher risk of a somatic stochastic effect, than the alternative technique (periapical

radiography).¹³

Because of this higher risk, it is not currently recommended that preoperative or intraoperative CBCT be taken for the purpose of estimating working length.¹⁴ However, evidence is growing in other areas, particularly within the fields of implantology, endodontics, and oral surgery, that in certain other situations the benefits of preoperative CBCT may outweigh the risks.¹⁵ It is therefore increasingly likely that a patient receiving root canal treatment either will need preoperative CBCT before treatment for another reason¹⁶ or may have recently had CBCT for other treatment, such as placement of an implant.¹⁵

The objective and rationale of this meta-analysis was to use a state-of-the-art evidence-based approach, utilizing statistical methods and aligning with the Preferred Reporting Items for Systematic Reviews and Meta-Analyses guidelines, to summarize the results of all available independent studies on the subject. This will provide a more precise estimate of the accuracy of preoperative CBCT in locating the AF and establish its usefulness in estimating the working length in teeth undergoing root canal treatment.¹⁷

Materials and Methods

A protocol was finalized after a brief pilot search, and the review was submitted for registration on the PROSPERO register in April 2019.

Six databases were searched by 2 authors in April 2019 and February 2020: MEDLINE, Embase, PubMed, Web of Science, Scientific Electronic Library Online, and the Cochrane Library. The MeSH terms “cone beam computed tomography,” “tooth apex,” “tooth root,” “root canal preparation,” “endodontics,” and “root canal therapy” were utilized. The keywords “CBCT,” “working length,” “apical foramen,” “tooth apex” “root canal length,” “root canal length determination,” “root canal length measurement,” and “root canal treatment” were also used.

Pre-specified study and report eligibility criteria were stated in the PICOS format.¹⁸ The population was teeth requiring root canal treatment, and the intervention was preoperative CBCT. The comparison was a suitable reference standard such as an *in vivo* EAL or *in vitro* assessment under magnification after extraction. The outcome was the determination of working length, and the included studies contained basic, observational, and interventional primary research, as well as secondary research. No restrictions were placed on language, publication date, or

publication status. Textbooks and leading journals were manually searched for additional articles, and gray literature was identified on the OpenGrey Database and Google Scholar.

Data were collected from articles that met the inclusion criteria, and authors were contacted to request any additional information required.

The risk of bias was assessed for randomized controlled trials with the Cochrane risk-of-bias tool¹⁹ and for basic research studies with the Office of Health Assessment and Translation risk-of-bias questions.²⁰

Heterogeneity was found in the outcome parameters utilized in the studies, with some using mean difference and others mean absolute difference. The 2 parameters could not be statistically combined and were therefore recorded separately. Attempts were made to contact all authors to obtain the raw data so that the outcome parameters could be combined; however, a response was only received from a single author.¹⁰

In addition to the 2 outcome parameters identified (mean

difference and mean absolute difference), 2 reference standards such as histology and EAL were also identified: histology and EAL. Due to the 2 outcome parameters and 2 reference standards included, 4 meta-analyses were planned to cover each combination. Because of the high levels of statistical heterogeneity, an inverse-variance random-effects model was chosen.¹⁹ Weighted mean differences were subsequently obtained with 95% confidence intervals and *P* values. The results were plotted as forest plots. The level of significance was set at 5%, and R version 3.0.2 software (R Foundation for Statistical Computing, Vienna, Austria; Metafor package) was used to perform the meta-analyses.

Results

Characteristics of included and excluded studies

Figure 1 shows the results of the search. Five studies were excluded because they used intraoperative rather than preoperative CBCT.²¹⁻²⁶ Two studies were excluded

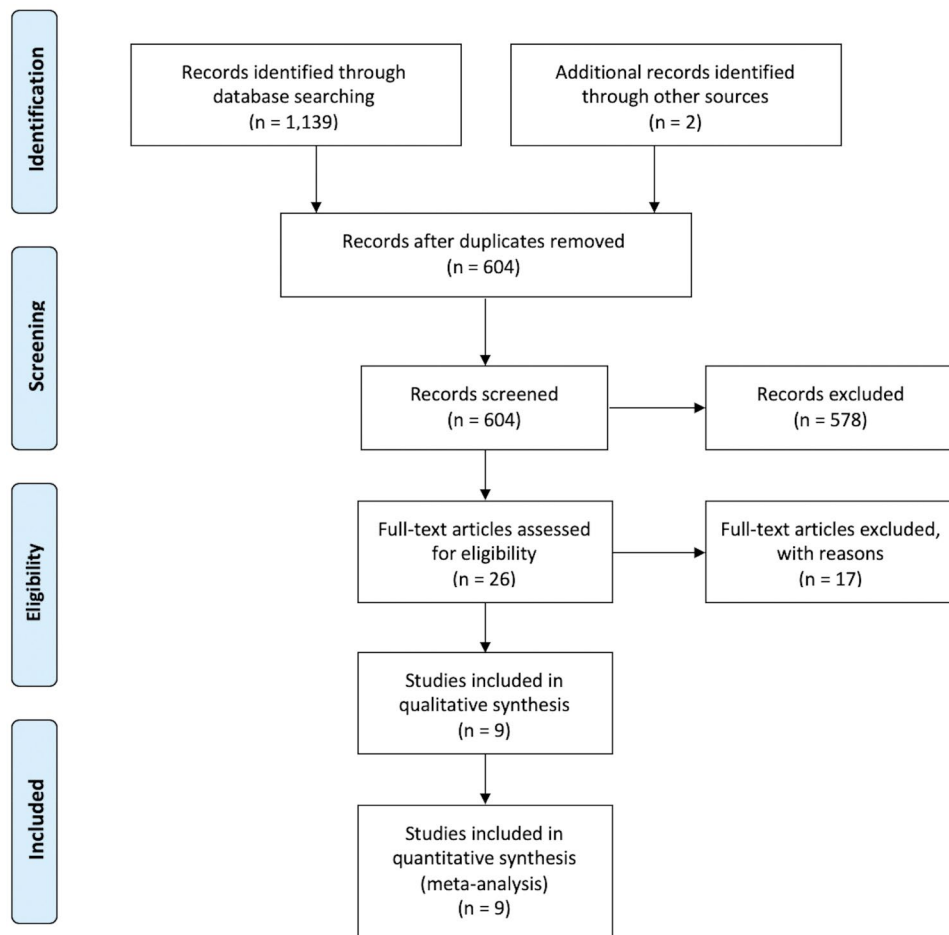


Fig. 1. Preferred Reporting Items for Systematic Reviews and Meta-Analyses (PRISMA) flow chart.

Table 1. General characteristics of the included studies

Authors	Study design	Tooth type	Arch	CBCT for index test	Reference test
Janner et al. 2011 ⁹	Randomized controlled cross-over trial	6 incisors 2 canines 1 premolar	2 maxillary 7 mandibular	3D Accuitomo XYZ slice view tomograph (0.08 mm voxel size, 6 × 6 cm FOV)	Root ZX EAL
Jeger et al. 2012 ¹¹	Randomized controlled cross-over trial	32 incisors 8 canines	36 maxillary 4 mandibular	3D Accuitomo XYZ slice view tomograph (0.08 mm voxel size, 4 × 4 cm × 6 cm or 8 × 8 cm FOV)	Root ZX EAL
Liang et al. 2013 ³⁸	Basic research on dry mandibles	74 anteriors 46 premolars 42 molars	0 maxillary 162 mandibular	3D Accuitomo CBCT (4 × 4 cm, 70 kVp, 3-5 mA, 17.5 second exposure time, 0.125 mm voxel size)	Direct measurement after extraction with caliper to the nearest 0.01 mm
Connert et al. 2014 ³⁵	Basic research on extracted teeth	12 incisors 6 canines 12 premolars 12 molars	28 maxillary 14 mandibular	KaVo 3D Exam (120 kV, 5 mA, 180° rotation, 0.2 mm voxel size)	Direct measurement after extraction with digital micrometer under × 4 magnification
Metska et al. 2014 ³⁹	Basic research on cadavers	15 incisors 7 canines 11 premolars 7 molars	33 maxillary 0 mandibular	3D Accuitomo 170 (90 kV, 5 mA, 360° rotation, standard resolution, 4 × 4 cm field of view, 0.125 mm voxel size)	Direct measurement after extraction under × 10 magnification with measuring software
Tchorz et al. 2014 ³⁴	Basic research on extracted teeth	20 molars	10 maxillary 10 mandibular	ProMax 3D (84 kV, 12 mA, 8 × 8 cm field of view, 0.2 mm voxel size)	Direct measurement after extraction with caliper to the nearest 0.01 mm
Aktan et al. 2016 ³⁶	Basic research on extracted teeth	30 anteriors	0 maxillary 30 mandibular	Planmeca ProMax 3D Mid (90 kV, 10 mA, 10 × 15 cm field of view, 0.2 mm voxel size)	Direct measurement after extraction with digital calipers
Üstün et al. 2016 ¹⁰	Randomized controlled cross-over trial	67 anteriors 6 premolars	Unclear	NewTom 5G (0.125 mm voxel size)	Propex Mini EAL and Rapex 6 EAL
Segato et al. 2018 ³⁷	Basic research on dry mandibles	30 premolars	0 maxillary 30 mandibular	Scanora 3D (90 kV, 13 mA, 60 × 60 cm field of view, 0.133 mm voxel size)	Direct measurement after extraction with caliper to the nearest 0.01 mm

EAL: electronic apex locator

Table 2. Summary of parameters and results for included studies

	Index measurement	Reference measurement	Sample size	Mean difference (mm)	Mean absolute difference (mm)
Janner et al. 2011 ⁹	Most incisal tooth edge to apical foramen	Most incisal tooth edge to EAL 'APEX' mark (length established on file, then file measured)	9	0.23 ± 0.61	0.40 ± 0.5
Jeger et al. 2012 ¹¹	Most incisal tooth edge to apical foramen	Most incisal tooth edge to EAL 'APEX' mark (length established on file, then file measured)	40		0.51 ± 0.45
Liang et al. 2013 ³⁸	In anteriors, the most incisal edge to apical foramen. In posteriors, the distance between the closest cuspidal edge in the projected extension line of the cervical one-third of the canal to the apical foramen.	The same coronal reference to the point at which the file is visible at the apical foramen under × 5 magnification (length established on file, then file measured with caliper to 0.01 mm)	198		0.46 ± 0.29
Connert et al. 2014 ³⁵	Highest point of corresponding cusp to apical foramen	Highest point of corresponding cusp to the point at which the file tip is flush with the lower border of the apical foramen under × 4 magnification (length established on file, then file measured with digital micrometer)	67		0.41 ± 0.35
Metska et al. 2014 ³⁹	Corresponding/adjacent cusp to major (apical) foramen	Corresponding/adjacent cusp to apical foramen (file cemented in canal at index measurement length before file tip and apical foramen location revealed by grinding apical tooth tissue; distance measured under × 10 magnification)	40	- 0.64 ± 0.82	
Tchorz et al. 2014 ³⁴	Cusp tip adjacent to the respective root canal to apical foramen	Cusp tip adjacent to the respective root canal to apical foramen to the point at which the file tip is tangential to the root surface with a stereomicroscope (length established on file, then file measured with digital caliper)	60		0.58 ± 0.39
Aktan et al. 2016 ³⁶	Occlusal plane to unmentioned apical reference	Occlusal plane to the point at which the file is adjacent to the most coronal border of the apical foramen under × 2.5 magnification (length established on file, then file measured with digital caliper)	30	0.26 ± 2.03	
Üstün et al. 2016 ¹⁰	Most incisal (or most cuspidal) tooth edge in the projected midline of the pulp cavity to major (apical) foramen	Incisal tooth edge to EAL '0' mark (length established on file, then file measured)	73	0.42 ± 1.3	0.99 ± 0.93
Segato et al. 2018 ³⁷	Flattened buccal cusp to apical foramen	Flattened buccal cusp to most coronal border of the apical foramen under × 10 magnification (length established on file, then file measured with digital caliper to 0.01 mm)	30	- 0.25 ± 0.41	

EAL: electronic apex locator

because they measured to the apical vertex rather than the apical foramen, resulting in a different measurement from the working length.^{27,28} One study was excluded due to the lack of a suitable reference standard.²⁹ Two studies included insufficient data for inclusion in the meta-analysis, and the authors could not be contacted to provide the missing data.^{30,31} One study involved the use of multidetector CT rather than CBCT,³² and 1 study was excluded since it was a systematic review of studies that had already been included.³³

The characteristics of the included studies are presented in Tables 1 and 2. In the 3 randomized controlled crossover-design trials, EALs were used as the reference standard (Table 1). Regarding outcomes, the mean difference was calculated in 2 studies, whereas the mean absolute difference could be calculated in all 3 studies (Table 2).

The remaining 6 studies were basic research studies with histological assessment as the reference standard (Table 1). Three were undertaken on extracted teeth,³⁴⁻³⁶ 2 on dry mandibles,^{37,38} and 1 on cadavers.³⁹ Regarding outcomes, the mean difference was calculated in 3 studies, whereas the mean absolute difference was calculated in the other 3 studies (Table 2).

Quality assessment

Figure 2 shows the risk of bias of the selected studies. The 3 studies using an EAL reference standard were crossover randomized controlled trials subjectively assessed to be at low risk of bias.⁹⁻¹¹ In all 3 trials, only a few minor sources of potential bias were present. First, we noted a failure to randomize the order in which CBCT and EAL readings were taken. However, this randomization would have been inappropriate, as in clinical settings, preoperative CBCT would always be taken before use of an EAL. Second, it was unclear how blinded the EAL and

CBCT operators were to the study conditions. Third, 1 study reported 10% attrition bias,⁹ and an unknown delay separated the date of the CBCT and EAL reading, during which time the position of the AF could have changed due to resorption.⁴⁰ Fifth, the potential for bias from the spill-over effect was present, as several subjects offered multiple teeth for the studies.

The studies using extracted teeth, dry mandibles, or cadavers and a histological reference standard were considered to have a high risk of bias due to the basic nature of the research.^{34-36,38,39}

Meta-analysis 1: CBCT identification of the AF position compared to histological measurements

Meta-analysis 1 estimated that CBCT measurements approximate the position of the AF to be 0.40 mm coronal of the histological assessment, and this difference was statistically significant (95% confidence interval, -0.71 mm to -0.10 mm) ($P=0.009$) (standard error, 0.15 mm). Both the I^2 (68.9%) and the Cochran Q values ($P<0.05$) suggested the presence of heterogeneity in the results; however, the tests lacked power and therefore could be misleading. With regard to publication bias, the Egger test indicated a lack of bias at $P=0.917$ (Fig. 3).

Meta-analysis 2: Difference between CBCT and histological measurements

Meta-analysis 2 estimated that CBCT measurements of the location of the AF were statistically significantly different from the histological assessments, with a weighted mean difference of 0.48 mm (95% confidence interval, 0.39 mm to 0.57 mm) ($P<0.001$) (standard error, 0.05 mm). Both the I^2 (77.5%) and the Cochran Q values ($P<0.05$) suggested the presence of heterogeneity in the results; however, the tests lacked power and therefore

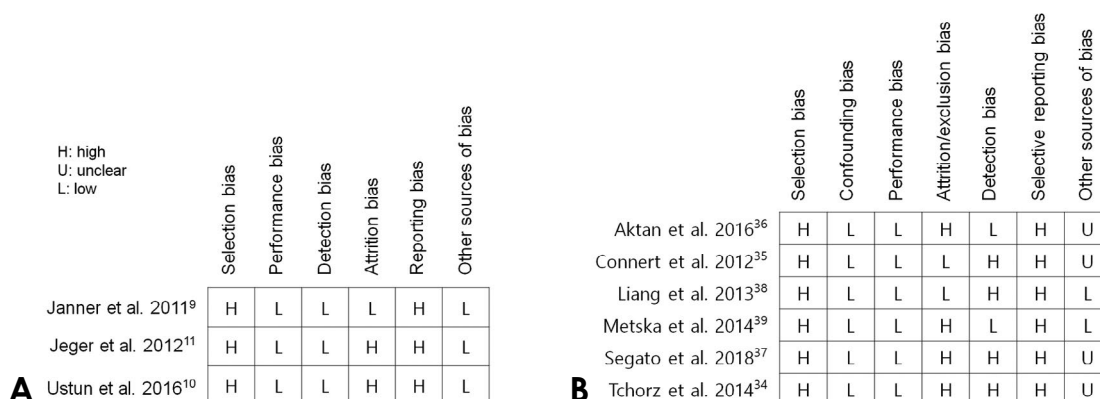


Fig. 2. Quality assessment of the selected studies. A. Randomized controlled crossover trials. B. Basic research studies.

could be misleading. With regard to publication bias, the Egger test indicated a lack of bias at $P=0.615$ (Fig. 3).

Meta-analysis 3: CBCT identification of the AF compared to EAL

Meta-analysis 3 estimated that there was no statistically significant difference in the location of the apical foramen as obtained with CBCT or EAL measuring techniques. The weighted mean difference placed the CBCT estimate slightly coronal of the EAL assessment at -0.11 mm; however, the confidence interval included zero (-0.75 mm to 0.53 mm) ($P=0.737$) (standard error, 0.32 mm). Both the I^2 (84.7%) and the Cochran Q values ($P<0.05$) suggested the presence of heterogeneity in the results; however, the tests lacked power and therefore could be misleading. The Egger test could not be conducted to evaluate publication bias due to an insufficient number of studies (Fig. 3).

Meta-analysis 4: Difference between CBCT and EAL measurements

Meta-analysis 4 estimated that CBCT measurements of the location of the AF were statistically significantly different from EAL assessments, with a weighted mean difference of 0.64 mm (95% confidence interval, 0.29 mm to 0.99 mm) ($P<0.001$) (standard error, 0.18 mm). Both the I^2 (87.5%) and the Cochran Q values ($P<0.05$) suggested the presence of heterogeneity in the results; however, the tests lacked power and therefore could be misleading. With regard to publication bias, the Egger test indicated a lack of bias at $P=0.788$ (Fig. 3).

Discussion

Following this systematic review and meta-analysis, it was possible to assess the accuracy of preoperative CBCT for locating the AF and assisting in establishing the endodontic working length.

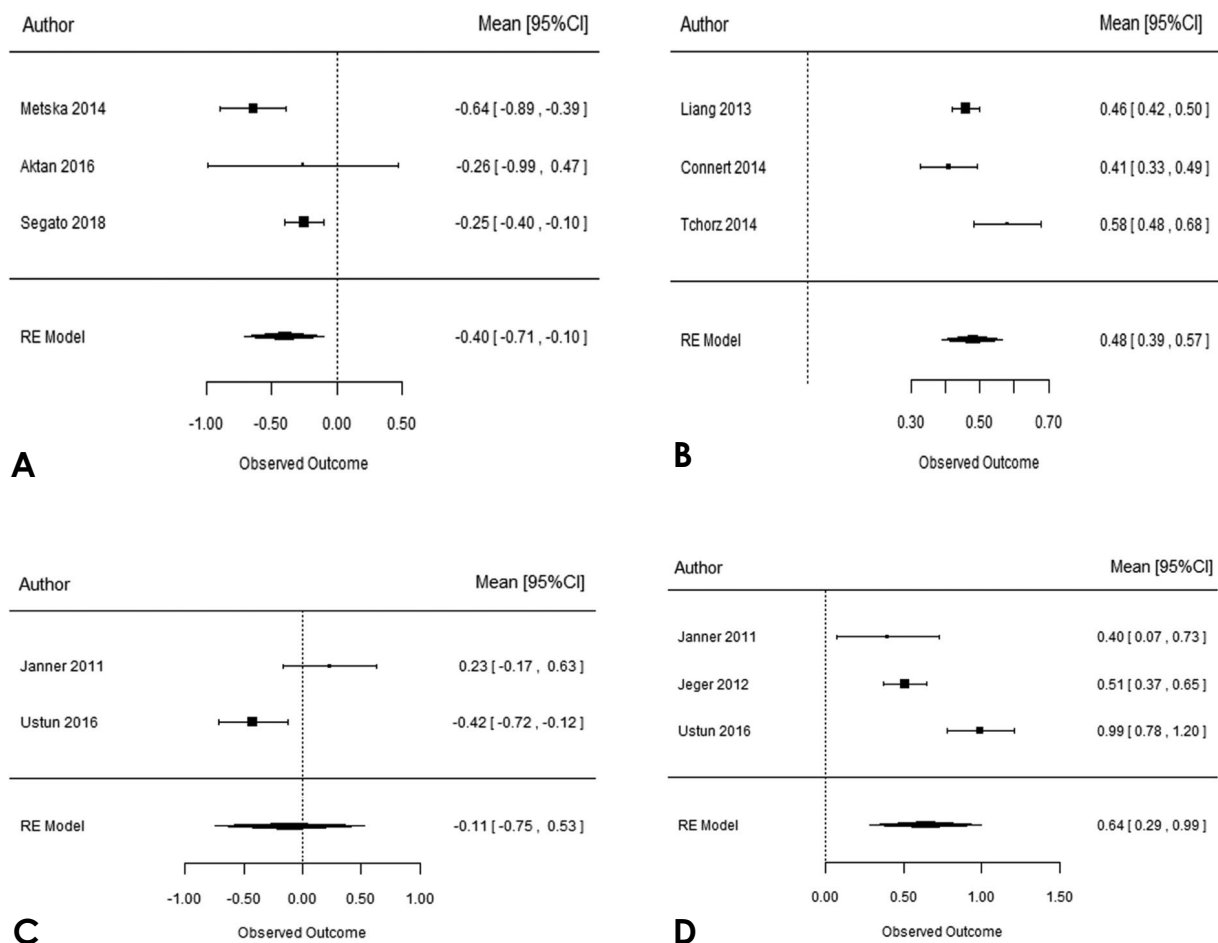


Fig. 3. A. Meta-analysis forest plots for histology and mean difference. B. Histology and mean absolute difference. C. Electronic apex locator (EAL) and mean difference. D. EAL and mean absolute difference.

Meta-analysis 1: CBCT identification of the AF position compared to histological measurements

The conclusions of this meta-analysis could be accepted as robust. Despite the evidence of heterogeneity obtained via the I^2 and Cochran Q test, all 3 studies were consistent in their assessment that CBCT estimated the AF to be coronal of the histological assessment by approximately 0.40 mm. The confidence intervals in 2 studies excluded zero, indicating a statistically significant difference.^{37,39} The third had a very wide standard deviation, so the confidence interval did not exclude zero.³⁶

Possible reasons for the larger standard deviation in the study by Aktan et al. include that the CBCT was taken at a slightly larger voxel size (0.2 mm compared to 0.133 mm and 0.125 mm), that slightly lower magnification was used for the histological assessments ($\times 2.5$ compared to $\times 10$), and that the apical reference for CBCT measurements was not explicitly stated in the study and thus may have been inconsistent (Tables 1 and 2, Fig. 3A).

Meta-analysis 2. Difference between CBCT and histological measurements

The conclusions of this meta-analysis could also be accepted as robust. Despite the evidence of heterogeneity obtained via the I^2 and Cochran Q tests, all 3 studies were consistent in their assessment that a statistically significant difference was present in the measurements made using CBCT and histological assessment. All 3 studies had narrow confidence intervals that excluded zero (Fig. 3B).

Meta-analysis 3: CBCT identification of the AF compared to EAL

This meta-analysis did not yield valid conclusions. The 2 included studies demonstrated a high level of heterogeneity in their I^2 and Cochran Q values, as well as disagreement regarding whether CBCT estimated the AF to be apical or coronal compared to an EAL reference standard. It is also important to note that the confidence intervals barely overlapped (Fig. 3C).

The heterogeneity in the results may have been due to the different EALs used in each of the studies, leading to differing capacity to detect the AF. Both studies were also conducted on teeth with large radiolucencies; this may have caused the resorption of apical landmarks, which is believed to affect EAL accuracy.⁴²

A recent systematic review on this subject also found no significant differences in measurements made by EAL and CBCT. However, those researchers also could not draw valid conclusions due to an insufficient sample size

and high levels of heterogeneity in equipment brands and outcome measurements.³³

Meta-analysis 4: Difference between CBCT and EAL measurements

This meta-analysis did not yield valid conclusions. The 3 studies demonstrated a high level of heterogeneity in their I^2 and Cochran Q values. It is also clear that the confidence intervals of Ustun et al. do not overlap with those of the other studies. This heterogeneity could have been due to the use of different EALs in the studies (Fig. 3D).¹⁰

Completeness and applicability of evidence

The conclusions of meta-analyses 1 and 2 could be considered robust from a statistical and methodological perspective, which made it relevant to answer the objectives of this meta-analysis. In terms of the completeness of the evidence, it would be beneficial to increase the number of studies in each of the 2 meta-analyses by obtaining raw data from research excluded due to heterogeneity in outcome parameters.

Regarding the applicability (or external validity) of the evidence, unidentified effect modifiers may be present and should be investigated. A particular issue was the time period between the CBCT and treatment, as the positions of the CRP and AF may change over time due to cementum deposition,^{1,43} apical inflammatory root resorption,⁴⁰ dental caries, tooth wear, or restorative treatment.

Another important potential effect modifier was the variation of working length during canal preparation. The distance between the CRP and AF tends to shorten by an average of 0.22 mm with the use of NiTi rotary files due to the straightening of any curvature.⁴³ The magnitude of this decrease has also been shown to be larger with stainless steel hand files than with NiTi rotary instruments due to the capacity of the latter to stay centered in the canal and reduce straightening. It has also been shown to be larger with aggressive coronal flaring - for example, with Gates-Glidden drills that remove cervical dentin - and in more curved canals.⁴³

Other unidentified effect modifiers may include tooth type, tooth age, presence of apical periodontitis and apical inflammatory root resorption, type of CBCT machine, tube voltage, tube current, image detector type, detector pixel size, number of basis projections, extent of rotational arc, size of field of view, voxel size, computed tomography reconstruction algorithm, image processing filters, viewing conditions, and viewing software.

The results from meta-analyses 3 and 4 were incom-

plete and lacked external validity.

Quality of evidence

Although the conclusions of meta-analyses 1 and 2 can be considered methodologically robust, the level of evidence they provide is undermined by the basic research upon which they are based. For this reason, the evidence level must be graded as very low according to the Grading of Recommendations, Assessment, Development, and Evaluation approach.¹⁹

The conclusions of meta-analyses 3 and 4 must also be triple-downgraded to very low due to indirectness through reference standard accuracy issues, heterogeneity and inconsistency of results, and imprecision of results as evidenced by wide confidence intervals.¹⁹

The main limitation of this review in terms of limiting bias is that not all of the available data could be used in each of the 4 meta-analyses. The use of the mean absolute difference as an outcome parameter alongside the mean difference was necessary due to the failure of many studies to report the latter.

In this study, a low level of evidence was produced to suggest that preoperative CBCT measures the AF to be on average 0.40 mm coronal to its histological position. Although this evidence is low-quality, it is the best currently available, and therefore it should be introduced as an additional tool to provide evidence of the distance between a CRP and the AF.

Conflicts of Interest: None

References

- Vertucci FJ. Root canal morphology and its relationship to endodontic procedures. *Endod Topics* 2005; 10: 3-29.
- Ricucci D, Langeland K. Apical limit of root canal instrumentation and obturation, part 2. A histological study. *Int Endod J* 1998; 31: 394-409.
- Ng YL, Mann V, Gulabivala K. A prospective study of the factors affecting outcomes of non-surgical root canal treatment: part 2: tooth survival. *Int Endod J* 2011; 44: 610-25.
- Hassanien EE, Hashem A, Chalfin H. Histomorphometric study of the root apex of mandibular premolar teeth: an attempt to correlate working length measured with electronic and radiograph methods to various anatomic positions in the apical portion of the canal. *J Endod* 2008; 34: 408-12.
- Citterio F, Pellegatta A, Citterio CL, Maddalone M. Analysis of the apical constriction using micro-computed tomography and anatomical sections. *G Ital Endod* 2014; 28: 41-5.
- Schell S, Judenhofer MS, Mannheim JG, Hülber-J M, Löst C, Pichler BJ, et al. Validity of longitudinal sections for determining the apical constriction. *Int Endod J* 2017; 50: 706-12.
- Connert T, Judenhofer MS, Hülber-J M, Schell S, Mannheim JG, Pichler BJ, et al. Evaluation of the accuracy of nine electronic apex locators by using Micro-CT. *Int Endod J* 2017; 51: 223-32.
- Chen E, Abbott PV. Evaluation of accuracy, reliability, and repeatability of five dental pulp tests. *J Endod* 2011; 37: 1619-23.
- Janner SF, Jeger FB, Lussi A, Bornstein MM. Precision of endodontic working length measurements: a pilot investigation comparing cone-beam computed tomography scanning with standard measurement techniques. *J Endod* 2011; 37: 1046-51.
- Üstün Y, Aslan T, Şekerci AE, Sağsen B. Evaluation of the reliability of cone-beam computed tomography scanning and electronic apex locator measurements in working length determination of teeth with large periapical lesions. *J Endod* 2016; 42: 1334-7.
- Jeger FB, Janner SF, Bornstein MM, Lussi A. Endodontic working length measurement with preexisting cone-beam computed tomography scanning: a prospective, controlled clinical study. *J Endod* 2012; 38: 884-8.
- Patel S, Dawood A, Whaites E, Pitt Ford T. New dimensions in endodontic imaging: part 1. Conventional and alternative radiographic systems. *Int Endod J* 2009; 42: 447-62.
- Ludlow JB, Timothy R, Walker C, Hunter R, Benavides E, Samuelson DB, et al. Effective dose of dental CBCT - a meta analysis of published data and additional data for nine CBCT units. *Dentomaxillofac Radiol* 2015; 44: 20140197.
- European Society of Endodontology. Quality guidelines for endodontic treatment: consensus report of the European Society of Endodontology. *Int Endod J* 2006; 39: 921-30.
- European Commission. Radiation Protection 136. European guidelines on radiation protection in dental radiology. Luxembourg: Office for Official Publications of the European Commission; 2004.
- Patel S, Brown J, Semper M, Abella F, Mannocci F. European Society of Endodontology position statement: use of cone beam computed tomography in Endodontics: European Society of Endodontology (ESE) developed by. *Int Endod J* 2019; 52: 1675-8.
- Higgins JP, Thomas J, Chandler J, Cumpston M, Li T, Page MJ, et al. *Cochrane handbook for systematic reviews of interventions*. Hoboken: Wiley; 2019.
- Liberati A, Altman DG, Tetzlaff J, Mulrow C, Gøtzsche PC, Ioannidis JP, et al. The PRISMA statement for reporting systematic reviews and meta-analyses of studies that evaluate health care interventions: explanation and elaboration. *PLoS Med* 2009; 6: e1000100.
- Higgins JP, Green S. *Cochrane handbook for systematic reviews of interventions*. Hoboken: Wiley-Blackwell; 2008.
- Rooney AA, Boyles AL, Wolfe MS, Bucher JR, Thayer KA. Systematic review and evidence integration for literature-based environmental health science assessments. *Environ Health Perspect* 2014; 122: 711-8.
- Lucena C, López JM, Martín JA, Robles V, González-Rodríguez MP. Accuracy of working length measurement: electronic apex locator versus cone-beam computed tomography. *Int Endod J* 2013; 47: 246-56.

22. Mrasori S, Budina R, Dragidella F. *In vitro* evaluation of three electronic apex locators using conventional methods and cone beam computed tomography. *Minerva Stomatol* 2014; 63: 259-66.
23. Elshinawy MI. In-vitro comparison of four different working length determination techniques. *Tanta Dent J* 2017; 14: 12-6.
24. Yildirim C, Aktan AM, Karataslioglu E, Aksoy F, Isman O, Culha E. Performance of the working length determination using cone beam computed tomography, radiography and electronic apex locator, in comparisons to actual length. *Iran J Radiol* 2017; 14: e13468.
25. Yılmaz F, Kamburoğlu K, Şenel B. Endodontic working length measurement using cone-beam computed tomographic images obtained at different voxel sizes and field of views, periapical radiography, and apex locator: a comparative ex vivo study. *J Endod* 2017; 43: 152-6.
26. Aleksandraa Đ, Irenaa KR, Milošb Ć, Ilijab V, Adrianac A, Teodorad U, Markod U, Draganad J. Root canal working length determination using cone beam computed tomography. *Serbian Dent J* 2019; 66: 57-65.
27. Sherrard JF, Rossouw PE, Benson BW, Carrillo R, Buschang PH. Accuracy and reliability of tooth and root lengths measured on cone-beam computed tomographs. *Am J Orthod Dentofacial Orthop* 2010; 137(4 Suppl): S100-8.
28. Yang H, Tian C, Li G, Yang L, Han X, Wang Y. A cone-beam computed tomography study of the root canal morphology of mandibular first premolars and the location of root canal orifices and apical foramina in a Chinese subpopulation. *J Endod* 2013; 39: 435-8.
29. Michetti J, Maret D, Mallet JP, Diemer F. Validation of cone beam computed tomography as a tool to explore root canal anatomy. *J Endod* 2010; 36: 1187-90.
30. Dhingra A, Dayal C, Singh A, Bhardwaj N. Predetermination of root canal lengths in molar teeth: A comparison between radiovisiography and two-dimensional and three-dimensional measurements using cone-beam computed tomography. *Indian J Dent* 2015; 6: 195-8.
31. de Moraes AL, de Alencar AH, Estrela CR, Decurcio DA, Estrela C. Working length determination using cone-beam computed tomography, periapical radiography and electronic apex locator in teeth with apical periodontitis: a clinical study. *Iran Endod J* 2016; 11: 164-8.
32. Dutta K, Desai PD, Das UK, Sarkar S. Comparative evaluation of three methods to measure working length - manual tactile sensation, digital radiograph, and multidetector computed tomography: an in vitro study. *J Conserv Dent* 2017; 20: 76-80.
33. Amin J, Lines J, Milosevic MP, Park A, Sholapurkar A. Comparison of accuracy and reliability of working length determination using cone beam computed tomography and electronic apex locator: a systematic review. *J Contemp Dent Pract* 2019; 20: 1118-23.
34. Tchorz JP, Poxleitner PJ, Stampf S, Patzelt SB, Rottke D, Hellwig E, et al. The use of cone beam computed tomography to predetermine root canal lengths in molar teeth: a comparison between two-dimensional and three-dimensional measurements. *Clin Oral Investig* 2014; 18: 1129-33.
35. Connert T, Hülber-J M, Godt A, Löst C, ElAyouti A. Accuracy of endodontic working length determination using cone beam computed tomography. *Int Endod J* 2014; 47: 698-703.
36. Aktan AM, Yildirim C, Karataşlıoğlu E, Çiftçi ME, Aksoy F. Effects of voxel size and resolution on the accuracy of endodontic length measurement using cone beam computed tomography. *Ann Anat* 2016; 208: 96-102.
37. Segato AV, Piasecki L, Felipe Iparraguirre Nuñovero M, da Silva Neto UX, Westphalen VP, Gambarini G, et al. The accuracy of a new cone-beam computed tomographic software in the preoperative working length determination ex vivo. *J Endod* 2018; 44: 1024-9.
38. Liang YH, Jiang L, Chen C, Gao X-J, Wesselink PR, Wu MK, et al. The validity of cone-beam computed tomography in measuring root canal length using a gold standard. *J Endod* 2013; 39: 1607-10.
39. Metska ME, Liem VM, Parsa A, Koolstra JH, Wesselink PR, Ozok AR. Cone-beam computed tomographic scans in comparison with periapical radiographs for root canal length measurement: an in situ study. *J Endod* 2014; 40: 1206-9.
40. Laux M, Abbott PV, Pajarola G, Nair PN. Apical inflammatory root resorption: a correlative radiographic and histological assessment. *Int Endod J* 2000; 33: 483-93.
41. Dunlap CA, Remeikis NA, BeGole EA, Rauschenberger CR. An in vivo evaluation of an electronic apex locator that uses the ratio method in vital and necrotic canals. *J Endod* 1998; 24: 48-50.
42. Martos J, Ferrer-Luque CM, González-Rodríguez MP, Castro LA. Topographical evaluation of the major apical foramen in permanent human teeth. *Int Endod J* 2009; 42: 329-34.
43. Davis D, Marshall G, Baumgartner R. Effect of early coronal flaring on working length change in curved canals using rotary nickel-titanium versus stainless steel instruments. *J Endod* 2002; 28: 438-42.