1998

Nitric oxide synthase expression in bone cells.

Fox, Simon

10.1016/s8756-3282(98)00070-2
Bone
Elsevier BV

Bone Vol. 23, No. 1
July 1998:1–6

ORIGINAL ARTICLES

Nitric Oxide Synthase Expression in Bone Cells

S. W. FOX and J. W. M. CHOW

Department of Histopathology, St. George's Hospital Medical School, Cranmer Terrace, London, UK

We have localized the expression of the three main nitric oxide synthases (eNOS, bNOS, and iNOS) in bone cells of rats and humans using immunohistochemistry. The predominant isoform expressed in normal adult bone was the constitutive isoform, eNOS, mainly in cells of osteoblastic lineage. In adult bone, the osteoblast lineage cells exhibiting eNOS expression were flat bone lining cells and osteocytes, but cuboidal osteoblasts were consistently negative. Expression for bNOS was not detected in any bone cells. iNOS expression was not detected in any cells of osteoblastic lineage in normal adult rat or human bone, but was observed in cuboidal osteoblasts of adult rats with experimental colitis, in which the suppression in bone formation may be cytokine mediated. Osteoclasts in normal rat tissue showed expression for both eNOS and iNOS, but these were patchy. As for cells of the osteoblast lineage, osteoclasts were negative for bNOS. Thus, our findings support evidence, from in vitro studies and from animal experiments, that nitric oxide may play an important role in the physiology of bone. (Bone 23:1–6; 1998)

Key Words: Nitric oxide synthase; Immunohistochemistry; Bone; Osteoblasts; Inflammation.

Introduction

Nitric oxide (NO) plays an important role as a mediator of diverse cellular functions in a variety of cell types, and is an effector of cytotoxicity in macrophage killing.[19,20] Its production is mediated by nitric oxide synthase, which is broadly divided into constitutive (cNOS) and inducible (iNOS) isoforms. The three most widely studied nitric oxide synthases are those present in the endothelium, brain, and macrophages.[20] A role for nitric oxide in bone has recently been suggested. Nitric oxide has been shown to modulate osteoclast recruitment and activity,[3,6,11,16,23] and nitric oxide is also thought to play a role in osteoblast function.

In vitro studies suggest that high levels of nitric oxide, as typically generated by iNOS, suppress osteoblast proliferation and differentiation, but that lower levels may stimulate osteoblast function.[24,25] Recently, osteoblastic cells have been shown to respond to mechanical strain and shear stress, resulting in a rapid increase in nitric oxide production.[8,22,27] Furthermore, in a rat-tail model of mechanical stimulation, the induction of new bone formation by mechanical loading was suppressed by administration of a nitric oxide synthase inhibitor, L-NMMA, before, but not after, a single episode of loading.[7] This suggests that the osteogenic response of bone to mechanical loading is dependent upon early production of nitric oxide.

We have also found, using an experimental model of inflammatory bowel disease, that cancellous bone formation is markedly suppressed in the presence of active colonic inflammation.[15] iNOS is known to be induced in osteoblasts by cytokines, such as interleukin-1 (IL-1), tumor necrosis factor-α (TNF-α), and interferon (INF).[5,10,24] Thus it is likely that these inflammatory mediators may induce iNOS expression in osteoblasts, and that the NO may be responsible for the suppression of bone formation.

Despite the apparent importance of nitric oxide in bone physiology, data on the localization of expression of nitric oxide synthase in bone cells in vivo are sparse.[9] In this communication, we have used immunohistochemistry to localize the expression of the three main nitric oxide synthases in the bone cells in normal rats and humans. We also investigated the expression of iNOS in osteoblasts in tibiae of rats with experimental colitis.

Materials and Methods

NOS Expression in Normal Bones

Four 13-week-old female Wistar rats were used. The rats were perfusion fixed with 4% paraformaldehyde in phosphate buffered saline (PBS). Tibiae and caudal vertebrae were then postfixed in the same fixative for 3 h and decalcified for 10 days in 10% ethylenediamine tetraacetic acid (EDTA)/PBS at 4°C. Three-day-old neonatal rats were also studied. These were fixed in 4% paraformaldehyde in PBS for 3 h and then decalcified for 24 h in 10% EDTA/PBS at 4°C. The rat tissues were processed through graded alcohols before embedding in wax. We also obtained four histologically normal human bone marrow trephines from patients without a history of malignant disease (age range 45–60 years). Lumbar vertebrae and ribs obtained from five fetuses (age range 16–32 weeks gestation) following acute intrauterine death were studied. The human bone tissues were fixed in buffered formal saline, decalcified for 2–3 days in 10% EDTA, processed, and embedded in wax. Sections 6 μm thick were used for immunohistochemistry.

Immunohistochemistry

Three antibodies reacting with the NOS proteins were used: polyclonal antihuman anti-bNOS, polyclonal antihuman eNOS, and polyclonal antimouse iNOS (Transduction Laboratories, Mamhead, Exeter, UK). The eNOS antibody was raised against a protein fragment corresponding to amino acids 1030–1209 of human eNOS. The bNOS antibody was raised against a protein fragment corresponding to amino acids 1383–1398 of human bNOS. The iNOS antibody was raised against residues 961–1144

Address for correspondence and reprints: Dr. J. W. M. Chow, Dept. of Histopathology, St. George's Hospital Medical School, Cranmer Terrace, London SW17 ORE, UK.

8756-3282/98/$19.00
PII S8756-3282(98)00070-2

Bone Vol. 23, No. 1
July 1998:1–6

of mouse iNOS. These have been shown to react against rat and human tissues. For the adult rat tissues, the anti-bNOS was used at a dilution of 1 in 800, the anti-eNOS at 1 in 800, and the anti-iNOS at 1 in 200. For the human bones, anti-bNOS was used at a dilution of 1 in 800, anti-eNOS at 1 in 3000, and anti-iNOS at 1 in 200. Most of the tissues used required 15–30 min trypsinisation prior to immunostaining. The primary antibody was incubated overnight at 4°C. A standard immunoperoxidase method utilizing an avidin–biotin conjugate was used (Dako, High Wycombe, Bucks, UK). Sections of normal rat ovary, cerebellum, and colon were used as positive controls for bNOS and eNOS. Ulcerated and inflamed rat colon was used as a positive control for iNOS. Negative controls comprised sections in which the primary antibody was replaced by nonimmune rabbit serum or in which the primary antibody was omitted.

NOS Expression in Rats With Experimental Colitis

Colitis was induced in 14-week-old male Wistar rats (500 g) by an intrarectal administration of trinitrobenzenesulphonic acid (TNBS) (Sigma, Poole, UK) (25 mg TNBS in 40% ethanol in normal saline buffered to pH 7.4) into the distal 7 cm of the colon and rectum, as previously described.[15] Control animals received intrarectal vehicle. Three weeks after TNBS or vehicle administration, the animals were killed in groups of five. Severe colitis (congestion and ulceration) was confirmed by macroscopic examination of the luminal surface of the colon. The left tibiae were removed and prepared for immunohistochemistry as described above.

NOS Expression in Bone Tumors

Three human osteoclastomas were studied.

Results

Specificity of staining was confirmed for the three antibodies used. bNOS positivity was observed in the molecular and granular layers of the cerebellum, and in ganglion cells and nonadrenergic, noncholinergic fibers of the colon (**Figure 1**). These cells did not stain with eNOS or iNOS. eNOS, but not bNOS or iNOS, positivity was observed in the vessels in the hilum of the ovary (Figure 1). eNOS positivity was consistently noted in the endothelium and media of blood vessels in the periosteal tissue attached to bone, but these vessels did not show immunoreactivity with bNOS. iNOS positivity was noted in macrophages in the ulcerated and inflamed colon. These cells did not stain with eNOS or bNOS. There was absence of positivity in all sections in which the primary antibody was replaced by nonimmune rabbit serum or was omitted.

Normal Bones

Constitutive NOS (eNOS). Similarities were observed in the cellular localization eNOS in adult rat tibia and vertebra. A prominent population of cells staining positively with eNOS were spindle-shaped cells in the primary spongiosa (**Figures 2 and 3**). These cells were often one cell layer thick, and either directly apposed onto the trabecular surface or overlying the layer of plump cuboidal osteoblasts covering the bone surface (Figures 2 and 3). This cell population was particularly notable in the adult rat tibia, and staining was less strong in the vertebrae. Plump cuboidal osteoblasts in the primary and secondary spongiosa and on the corticoendosteal surface were consistently negative for eNOS (Figures 2 and 3). We also noted positivity for eNOS in flat bone lining cells on the trabecular surface in the

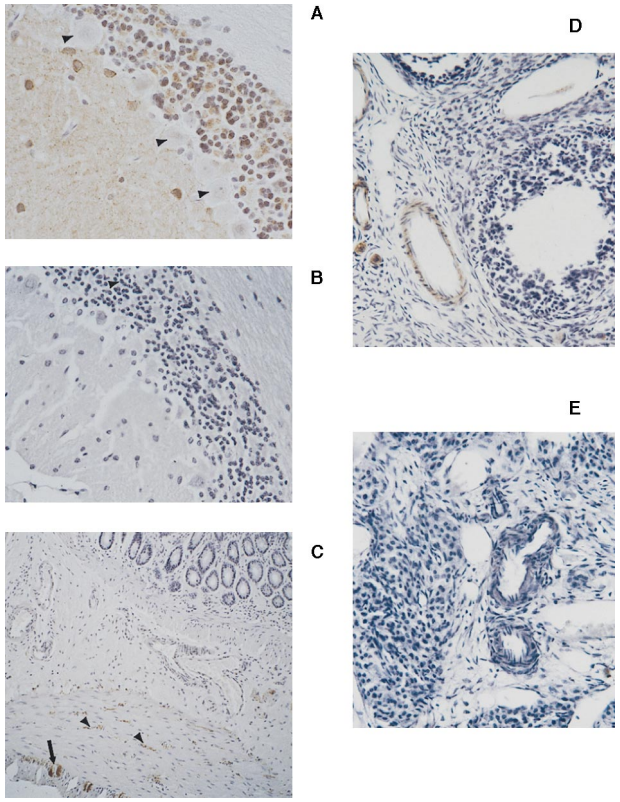

Figure 1. A, B: The cells in the granular and molecular layers of adult rat cerebellum stained positively with bNOS (A) (original magnification ×250), but not eNOS (B) (original magnification ×160). Purkinje cells (arrowheads) did not react with bNOS. C: The ganglion cells (arrow) and nonadrenergic, noncholinergic fibers (arrowhead) of adult rat colon stained positively with bNOS. Original magnification ×100. D, E: Blood vessels in the hilum of the adult rat ovary stained with eNOS (D), but not bNOS (E). Original magnification ×160.

secondary spongiosa of the tibia and, to a lesser extent, vertebra (Figures 2 and 3). A population of spindle cells overlying plump cuboidal osteoblasts on the corticoendosteal surface, similar to those seen in the primary spongiosa, also exhibited strong positivity with eNOS (Figure 2). A proportion of osteocytes, both in the trabecular and cortical bone, stained positively with eNOS (Figures 2 and 3).

The predominant population of chondrocytes exhibiting eNOS positivity were the hypertrophic and intermediate chondrocytes (Figure 3). Occasional osteoclasts within the primary spongiosa were weakly positive with eNOS. No consistent pattern of positivity, depending on the proximity of the osteoclasts to resorbing bone surfaces, was noted. Osteoclasts on the periosteal surface of the metaphyseal cortex were positive with eNOS (**Figure 4**). The plump osteoblasts and layer of spindle cells over the periosteal surface were negative for eNOS.

In neonatal rat bone, chondrocytes, osteoclasts, and osteoclast-like cells (Figure 3) were strongly positive with eNOS. Like the adult rat, the spindle shaped cells overlying plump cuboidal osteoblasts in the primary spongiosa stained positively with eNOS, but the cuboidal osteoblasts themselves were negative (Figure 3). A few spindle-shaped stromal cells within the marrow also exhibited positivity with eNOS. No positivity was noted in osteocytes. None of the other cells in the bone or bone marrow demonstrated convincing positivity in our hands.

Flat bone lining cells covering the trabecular bone surface in

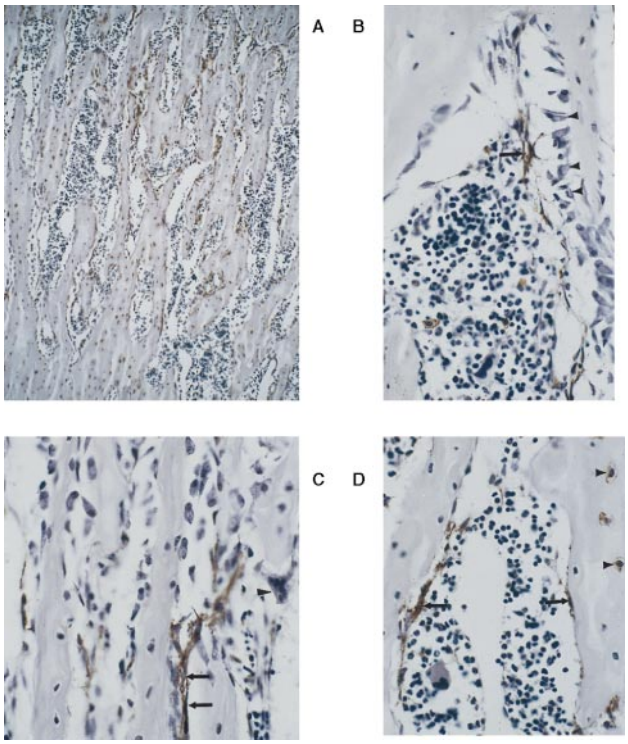

Figure 2. A: Low power photomicrograph of adult rat tibia stained with eNOS (original magnification ×40). Osteocytes and bone surface cells stained positively. B, C: High power photomicrographs (original magnification ×250) of corticoendosteal surface (B) and primary spongiosa (C) of adult rat tibia stained with eNOS. The spindle-shaped cells overlying the plump osteoblasts (arrow) stained positively, but plump osteoblasts (arrowheads) were negative. The osteoclast present (C) in this field was negative. D: Bone lining cells (arrows) and osteocytes (arrowheads) in the secondary spongiosa of adult rat tibia stained positively with eNOS. Original magnification ×250.

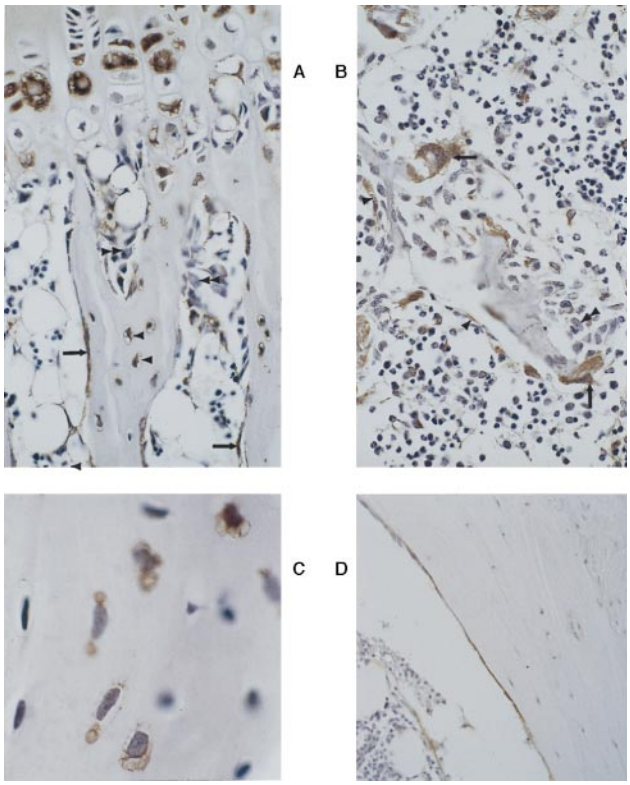

Figure 3. A: High power photomicrograph of adult rat caudal vertebra stained with eNOS. Chondrocytes stained positively. Flat bone lining cells (arrows) and osteocytes (arrowheads) showed immunoreactivity with eNOS. Plump osteoblasts (double arrowheads) were negative. Original magnification ×250. B: High power photomicrograph of neonatal rat tibia stained with eNOS. Osteoclasts (arrows) and some spindle-shaped cells (arrowheads) stained positively, but plump osteoblasts (double arrows) were negative. Original magnification ×250. C: High power photomicrograph of cortex of adult rat vertebra stained with eNOS. The scanty cytoplasm and cell processes of osteocytes showed immunoreactivity. Original magnification ×1000. D: Flat bone lining cells on surface of adult human bone stained positively with eNOS. Original magnification ×100.

human iliac crest were strongly positive with eNOS (Figure 3). No positivity was noted in osteocytes. Osteoclasts and plump osteoblasts were not seen in any of these trephine biopsies. All other hemopoietic elements were negative.

Chondrocytes of the vertebra and costochondral junction of human fetal bones were positive with eNOS. We did not detect immunoreactivity with eNOS in plump cuboidal osteoblasts, osteoclasts, osteocytes, or periosteal spindle cells.

Constitutive NOS (bNOS). None of the bone cells of the osteoblastic lineage or the osteoclasts exhibited positivity for bNOS in any of the adult or fetal rat or human bones examined.

Inducible NOS (iNOS). The immunohistochemical profile with iNOS was different from that of the two constitutive enzymes.

The only cells in the normal adult rat tibia and vertebra exhibiting positivity with iNOS were osteoclasts. The osteoclasts on the periosteal surface of the metaphyseal cortex were generally strongly positive, but osteoclasts in the primary spongiosa were rarely positive. Osteoblasts, bone lining cells, osteocytes, and chondrocytes were consistently negative. In the neonatal rat bone, osteoclasts and osteoclast-like cells showed immunoreactivity with iNOS, but all other cells were negative (Figure 4).

No immunoreactivity was observed in any cells in the human iliac bone or marrow.

Chondrocytes in human and rat fetal bones were negative for iNOS. Osteoclasts within the area of endochondral ossification in human fetal lumbar vertebrae were positively stained (Figure 4). Cuboidal osteoblasts on the bony trabeculae were negative for iNOS.

NOS Expression in Tibiae of Rats With Experimental Colitis

Plump cuboidal osteoblasts in the primary spongiosa and on the corticoendosteal surface of tibiae of animals with experimental colitis exhibited strong positivity with iNOS (**Figure 5**). Chondrocytes and young osteocytes were also positive for iNOS. A few osteoclasts also stained weakly positively, as in the normal animals. As in normal animals, cuboidal osteoblasts were consistently negative in the control animals treated with intrarectal vehicle.

Osteoclastoma

A high proportion of mononuclear stromal cells in the osteoclastomas exhibited strong cytoplasmic positivity for eNOS but not bNOS. The osteoclasts were either negative or showed weak positivity for eNOS (Figure 5). Unlike eNOS, mononuclear

Bone Vol. 23, No. 1
July 1998:1–6

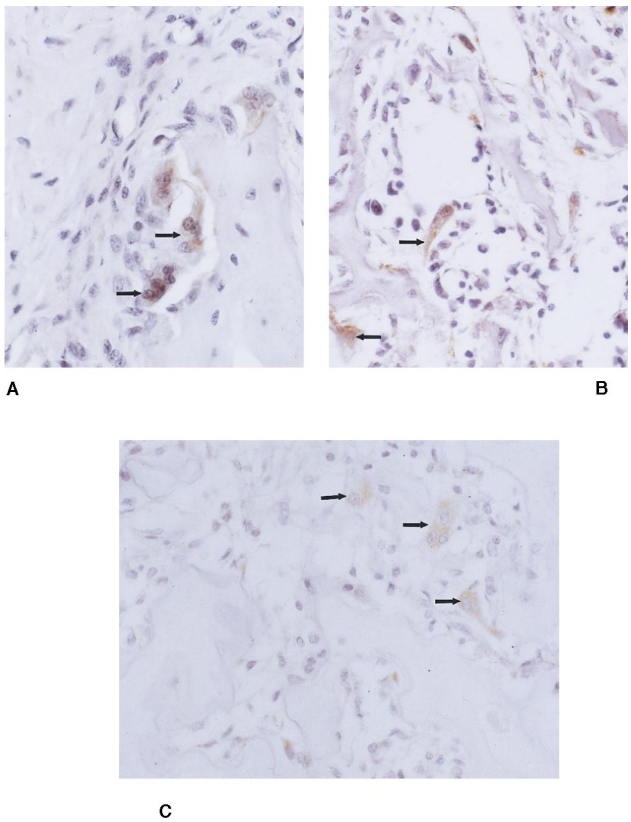

Figure 4. A: High power photomicrograph (original magnification ×400) of adult rat tibia stained with eNOS. The osteoclasts (arrows) on the periosteal surface of the metaphysis showed positivity for eNOS. B, C: High power photomicrograph (original magnification ×400) of neonatal rat tibia (B) and human fetal lumbar vertebra (C) stained for iNOS. Osteoclasts (arrows) showed immunoreactivity for iNOS. Osteoblasts, stromal, and hemopoietic cells were negative.

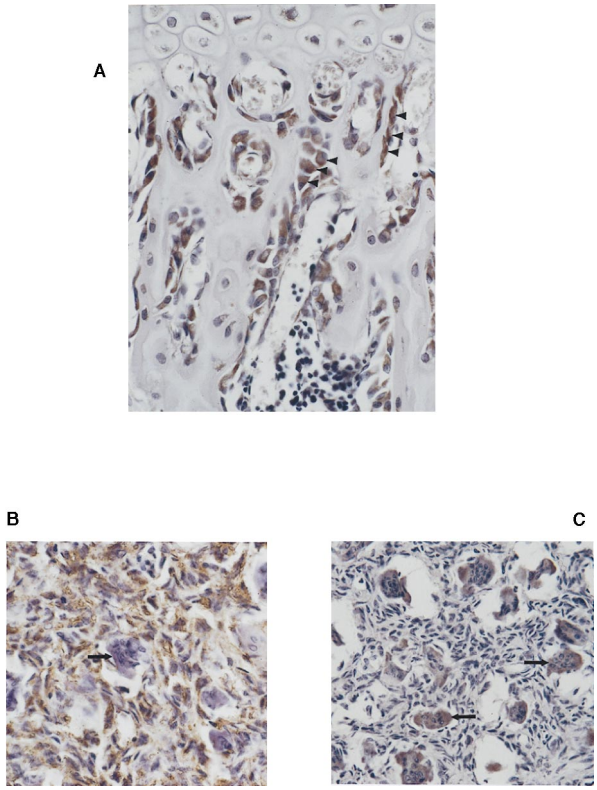

Figure 5. A: High power photomicrograph of adult tibia of rat with experimental colitis stained with iNOS. In contrast to eNOS, plump osteoblasts stained strongly with iNOS. Original magnification ×250. B, C: Photomicrographs of osteoclastoma stained with eNOS (B) (original magnification ×160) and iNOS (C) (original magnification ×100). Most of the stromal cells stained with eNOS, but osteoclasts (arrowhead) were largely negative. The converse was observed with iNOS; osteoclasts showed immunoreactivity but the stromal cells did not.

stromal cells in the osteoclastomas were negative for iNOS, but the numerous osteoclasts that are characteristic of the tumor showed strong positivity (Figure 5).

Discussion

We present the first detailed immunohistochemical study of nitric oxide synthases in bone cells in rats and humans in vivo. Previous investigations of the expression of nitric oxide synthases in bone have centered on cells in tissue culture.[3,24,25] The main enzyme that has been detected in bone cells using these techniques is the inducible isoform, together with smaller quantities of bNOS.[24,25] This is not surprising, because iNOS is upregulated by numerous cytokines present in tissue culture.

Our results show that although both constitutive and inducible isoforms of NOS are expressed in bone, the nitric oxide synthase that is widely distributed in bone cells is the constitutive isoform, eNOS, predominantly in cells of osteoblastic lineage.

Our results also show that rats and humans share many similarities in the population of bone cells that exhibit immunoreactivity with eNOS. Inactive flat bone lining cells on the trabecular bone surface of the rat secondary spongiosa and on human cancellous bone exhibit positivity, whereas plump cuboidal active osteoblasts are uniformly negative. We also noted positivity in a proportion of cortical and trabecular osteocytes. The distribution of osteocytes exhibiting immunoreactivity was patchy throughout the metaphyseal and diaphyseal cortex.

Although it is well known that mechanical stimulation is a potent stimulus for bone formation, the mechanisms by which this is detected, and subsequently transduced into bone formation, are still poorly understood. The prime candidate, the mechanosensory cell in bone, is thought to be the osteocyte.[4,17] These are entombed in the bone matrix, and form an interconnecting network with each other and with bone lining cells. It is interesting that we found that osteocytes and flat bone lining cells showed immunoreactivity for eNOS. We have previously shown that administration of L-NMMA to animals shortly before a 5-min episode of mechanical loading suppresses the osteogenic response to mechanical stimulation, whereas L-NMMA given 2 h after loading had no effect.[7] This suggests that nitric oxide plays an important role in the transduction of mechanical stimulation into subsequent bone formation, and that the enzyme involved is constitutively expressed. eNOS, although constitutively present, has been shown to be induced by a variety of stimuli including shear stress, hypoxia, and estrogen.[1,14,28]

Shear stress may be a mechanism by which eNOS may be upregulated in bone cells.[8,14,27] The differential expression of this constitutive isoform of NOS in osteoblastic cells of various differentiation that we have observed is also in keeping with in vitro evidence, suggesting a differential response of mature osteoblasts and osteocytes to mechanical stimulation.[12,17,22]

We were unable to detect immunoreactivity for eNOS in

osteocytes and bone lining cells in neonatal and fetal bone. These cell types are scanty in these developing bones. It is also possible that NOS may be acquired in these bone cells during the developmental process, for example, as has been demonstrated with iNOS expression.[2] Alternatively, lack of expression of eNOS in these cells may be related to the lack of mechanical strain in rats and humans at these stages of development. Thus the acquisition of eNOS expression by osteocytes may be related to differentiation and function.

Another population of cells expressing eNOS are spindle cells overlying the cuboidal osteoblasts in the primary spongiosa and corticoendosteal surface of normal adult and fetal rat bones. Although the nature of these cells is uncertain, a proportion of them are likely to be osteogenic progenitors.[21] The role of NO in these cells is also unclear.

Unlike the constitutive isoform, none of the cells of osteoblast lineage in normal adult rat and human bone expressed iNOS. It has previously been shown that inflammatory cytokines, such as IL-1, TNF-α, and INF, induce iNOS expression in osteoblasts in vitro, and that NO produced under these circumstances suppresses osteoblast proliferation and differentiation.[10,24] The induction of iNOS expression in plump cuboidal osteoblasts in the tibiae of rats with experimental colitis is in keeping with suppression of cancellous bone formation in these animals.[15] Thus it is possible that cytokines in the circulation or produced by peripheral monocytes as a result of systemic inflammation may induce iNOS expression in osteoblasts, and that the large amounts of NO produced are responsible for the suppression of bone formation observed in systemic inflammation.[15,18] Induction of iNOS expression in brain cells has also been noted in systemic inflammation,[29] and local inflammatory diseases such as experimental encephalitis.[13]

Like some investigators, we have found expression of both inducible and constitutive isoforms of NOS in osteoclasts in normal bone.[3] This was weak and patchy in adult rat bone, but strong expression was observed in osteoclasts and osteoclast-like cells in neonatal rat bone. We are unable to explain the lack of corresponding findings in human fetal bone. Despite careful selection of the tissues, by clinical history and autopsy findings, we cannot entirely exclude the possibility that inflammatory cytokines may be stimulated in these fetuses, thereby upregulating iNOS expression. Other investigators, however, have been unable to detect iNOS in osteoclasts by immunohistochemical techniques.[9] The reasons for the variable results are unclear, but may be related to differences in fixation and processing of tissue, or in methods utilized in unmasking of the antigen prior to immunostaining. Nevertheless, immunoreactivity for both eNOS and iNOS in osteoclasts was patchy, and we did not find a consistent relationship of positivity with resorbing surfaces.

The only bone tumor we studied was osteoclastoma. The histogenesis of the neoplastic component of osteoclastomas is not known, but these cells are generally considered to be of osteoblast lineage.[26] Thus it is interesting that they share the immunohistochemical profile of normal osteoblastic cells. Osteoclasts, which are thought to be reactive cells in this tumor, like their normal counterpart, show immunoreactivity for iNOS. The widespread positivity for iNOS in osteoclasts in these tumors may reflect the abnormal milieu in which the osteoclasts are found.

In summary, the predominant isoform expressed in osteoblastic cells of normal adult bone was eNOS. The expression of eNOS also showed a strong relationship with the state of differentiation of the osteoblastic lineage. We have also shown that iNOS expression in osteoblasts may be upregulated by systemic inflammation in vivo. Although the mechanisms by which these occur are poorly understood, the widespread and diverse distribution of NOS in bone, and the morphological and functional evidence of a modulatory role for NO that we present support data from in vitro studies and from animal experiments, that nitric oxide plays an important role in regulating bone formation and bone resorption. It would be interesting to study changes in NOS expression in reactive and other abnormal human bone, such as Paget's disease, fracture callus, and hyperparathyroidism.

Acknowledgments: The authors wish to thank V. Emmons for assistance with preparation of the manuscript. This work was supported by the Arthritis and Rheumatism Council and the Wellcome Trust.

References

1. Arnett, U. A., McMillan, A., Dinerman, J. L., Ballermann, B., and Lowenstein, C. J. Regulation of endothelial nitric-oxide synthase during hypoxia. J Biol Chem 271:15069–15073; 1996.
2. Baylis, S. A., Weiner, C. P., Moncada, S., and Charles, J. C. In vitro expression of inducible nitric oxide synthase in the human fetus. In: International Conference on Biochemistry and Molecular Biology of Nitric Oxide, Los Angeles, CA; 1994; p. 66, Abstract A3.
3. Brandi, M. L., Hukkanen, M., Umeda, T., Moradi-Bidhendi, N., Bianchi, S., Gross, S. S., Polak, J. M., and MacIntyre, I. Bidirectional regulation of osteoclast function by nitric oxide synthase isoforms. Proc Natl Acad Sci USA 92:2954–2958; 1995.
4. Cowin, S. C., Moss-Salentijn, L., and Moss, M. L. Candidates for the mechanosensory system in bone. J Biomech Eng 113:191–197; 1991.
5. Damoulis, P. D. and Hauschka, P. V. Cytokines induce nitric oxide production in mouse osteoblasts. Biochem Biophys Res Commun 201:924–931; 1994.
6. Evans, D. M. and Ralston, S. H. Nitric oxide and bone. J Bone Miner Res 11:300–305; 1996.
7. Fox, S. W., Chambers, T. J., and Chow, J. W. M. Nitric oxide is an early mediator of the increase in bone formation by mechanical stimulation. Am J Physiol 270:E955–E960; 1996.
8. Frangos, J. A. and Johnson, D. Flow stimulates rapid and continuous release of nitric oxide in osteoblasts. FASEB J 4:A673; 1995.
9. Helfrich, M. H., Evans, D. E., Grabowski, P. S., Pollock, J. S., Ohshima, H., and Ralston, S. H. Expression of nitric oxide synthase isoforms in bone and bone cell cultures. J Bone Miner Res 12:1108–1115; 1997.
10. Hukkanen, M., Hughes, F. J., Buttery, L. D. K., Gross, S. S., Evans, T. J., Seddon, S., Riveros-Moreno, V., MacIntyre, I., and Polak, J. M. Cytokine-stimulated expression of inducible nitric-oxide synthase by mouse, rat, and human osteoblast-like cells and its functional role in osteoblast metabolic activity. Endocrinology 136:5445–5453; 1995.
11. Kasten, T. P., Collin-Osdoby, P., Patel, N., Osdoby, P., Krukowski, M., Misko, T. P., Settle, S. L., Currie, M. G., and Nickols, G. A. Potentiation of osteoclast bone-resorption activity by inhibition of nitric oxide synthase. Proc Natl Acad Sci USA 91:3569–3573; 1994.
12. Klein-Nulend, J., Semeins, C. M., Ajubi, N. E., Nijweide, P. J., and Burger, E. H. Pulsating fluid flow increases nitric oxide (NO) synthesis by osteocytes but not periosteal fibroblasts—correlation with prostaglandin upregulation. Biochem Biophys Res Commun 217:640–648; 1995.
13. Koprowski, H., Zheng, Y. M., Heber-Katz, E., Fraser, N., Rorke, L., Fu, Z. F., Hanlon, C., and Dietzschold, B. In vivo expression of inducible nitric oxide synthase in experimentally induced neurologic diseases. Proc Natl Acad Sci USA 90:3024–3027; 1993.
14. Kuchan, M. J. and Frangos, J. A. Role of calcium and calmodulin in flow-induced nitric oxide production in endothelial cells. Am J Physiol 266:C628–C636; 1994.
15. Lin, C.-L., Moniz, C., Chambers, T. J., and Chow, J. W. M. Colitis causes bone loss in rats through suppression of bone formation. Gastroenterology 111: 1263–1271; 1996.
16. Löwik, C. W. G. M., Nibbering, P. H., van de Ruit, M., and Papapoulos, S. E. Inducible production of nitric oxide in osteoblast-like cells and in fetal mouse bone explants is associated with suppression of osteoclastic bone resorption. J Clin Invest 93:1465–1472; 1994.
17. Mikuni-Takagaki, Y., Suzuki, Y., Kawase, T., and Saito, S. Distinct responses of different populations of bone cells to mechanical stress. Endocrinology 137:2028–2035; 1996.
18. Minne, H. W., Pfeilschifter, J., Scharla, S., Mutschelknauss, S., Schwarz, A.,

Krempien, B., and Ziegler, R. Inflammation-mediated osteopenia in the rat: A new animal model for pathological loss of bone mass. Endocrinology 115:50–54; 1984.

19. Moncada, S., Palmer, R. M. J., and Higgs, E. A. Nitric oxide: Physiology, pathophysiology, and pharmacology. Pharmacol Rev 43:109–142; 1991.
20. Nathan, C. Nitric oxide as a secretory product of mammalian cells. FASEB J 6:1051–1064; 1992.
21. Owen, M. E. and Friedenstein, A. J. Stromal stem cells: Marrow-derived osteogenic precursors. In: Ciba Foundation Symposium No. 136. Chichester: Wiley; 1988; 42–60.
22. Pitsillides, A. A., Rawlinson, S. C. F., Suswillo, R. F. L., Bourrin, S., Zaman, G., and Lanyon, L. E. Mechanical strain induced NO production by bone cells: A possible role in adaptative bone (re)modelling? FASEB J 9:1614–1622; 1995.
23. Ralston, S. H., Ho, L.-P., Helfrich, M. H., Grabowski, P. S., Johnston, P. W., and Benjamin, N. Nitric oxide: A cytokine-induced regulator of bone resorption. J Bone Miner Res 10:1040–1049; 1995.
24. Ralston, S. H., Todd, D., Helfrich, M., Benjamin, N., and Grabowski, P. S. Human osteoblast-like cells produce nitric oxide and express inducible nitric oxide synthase. Endocrinology 135:330–336; 1994.
25. Riancho, J. A., Salas, E., Zarrabeitia, M. T., Olmos, J. M., Amado, J. A., Fernandez-Luna, J. L., and Gonzalez-Macias, J. Expression and functional role of nitric oxide synthase in osteoblast-like cells. J Bone Miner Res 10:439–446; 1995.
26. Robinson, D. and Einhorn, T. A. Giant cell tumor of bone: A unique paradigm of stromal-hematopoietic cellular interactions. J Cell Biochem 55:300–303; 1994.
27. Smalt, R., Mitchell, F. T., Howard, R. L., and Chambers, T. J. Mechanical strain versus wall shear stress as the stimulus to bone cells in mechanical loading (abstract). J Bone Miner Res 11(Suppl. 1):S265; 1996.
28. Weiner, C., Baylis, S., Lizasoain, I., Knowles, R., Charles, I., and Moncada, S. Induction of calcium-dependent nitric oxide synthases by sex hormones. Proc Natl Acad Sci USA 91:5212–5216; 1994.
29. Wong, M.-L., Rettori, V., Al-Shekhlee, A., Bongiorno, P. B., Canteros, G., McCann, S. M., Gold, P. W., and Licinio, J. Inducible nitric oxide synthase gene expression in the brain during systemic inflammation. Natl Med 2:581–584; 1996.

Date Received: May 30, 1997
Date Revised: March 20, 1998
Date Accepted: March 20, 1998